

Available online at www.sciencedirect.com

ScienceDirect

journal homepage: www.elsevier.com/locate/radcr

Case Report

Breast hemangioma in a male patient: Report of a case

Sebastian Isaza Zapata^a, Ricardo Uribe González^{b,*}, Carlos Mario González Vasquez^c

^aRadiology Resident at Universidad CES, Medellín, Colombia

^bGeneral Radiologist at CediMed, Medellín, Colombia

^cGeneral Radiologist at CediMed and Hospital Pablo Tobón Uribe, Radiology Professor at Universidad CES and Universidad Pontificia Bolivariana, Medellín, Colombia

ARTICLE INFO

Article history:

Received 13 December 2018

Revised 5 January 2019

Accepted 6 January 2019

Available online 16 January 2019

Keywords:

Hemangioma

Breast

Breast neoplasms

ABSTRACT

Breast hemangioma is a rare benign tumor in female and extremely rare in males. They are part of vascular tumors. Here, we described the case of a male patient who had a breast hemangioma for 30 years that was diagnosed incidentally in a thorax and abdomen tomography. We briefly review epidemiology, histopathology, clinical, and imaging findings related to breast hemangioma.

© 2019 The Authors. Published by Elsevier Inc. on behalf of University of Washington.

This is an open access article under the CC BY-NC-ND license.

(<http://creativecommons.org/licenses/by-nc-nd/4.0/>)

Introduction

The hemangioma is a rare benign tumor of the breast in females and an extremely rare tumor in male breast [1,2], with unknown incidence [1] and very few cases reported in the literature. The hemangiomas are benign vascular tumors composed of dilated vascular channels lined with flattened endothelial cells without atypia [3]. Hemangiomas of the breast may be further sub classified into capillary, cavernous, venous, and perilobular subtypes, capillary and cavernous being the most common [3–5]. Imaging findings are nonspecific and definite diagnosis is given by histological analysis with specific vascular markers.

Case Presentation

We present the case of 54-year-old male who was admitted to the Emergency department for 40°C fever, severe headache, diarrhea, and diffuse abdominal pain. The patient had pain and tenderness in the right upper abdominal quadrant to palpation, with normal vital signs. In this setting, an abdominal computed tomography was ordered, which revealed a small hypervascular lesion in the left breast (Fig. 1). The patient was evaluated by a breast and soft-tissue surgeon who reinterrogated the patient about the mass. The patient referred he had the lesion for over 30 years with occasional pain and tenderness over the area of concern. The medical staff ordered a

Competing Interests: The authors have declared that no competing interests exist.

* Corresponding author.

E-mail address: ricardouribegonzalez@gmail.com (R. Uribe González).

<https://doi.org/10.1016/j.radcr.2019.01.002>

1930-0433/© 2019 The Authors. Published by Elsevier Inc. on behalf of University of Washington. This is an open access article under the CC BY-NC-ND license. (<http://creativecommons.org/licenses/by-nc-nd/4.0/>)

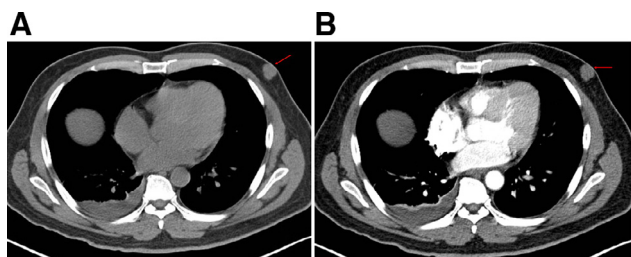


Fig. 1 – CT without (A) and with contrast (B) showing a lobulated mass located in the left breast without calcifications or skin retraction. Enhancement is seen after the contrast administration. There is also right pleural effusion with atelectasis.

mammogram and biopsy. On the mammogram a well-defined mass in the left lower outer quadrant is visualized, no spiculation or microcalcifications are seen (Fig. 2). The patient went to surgery and the pathology reported a well-defined mass, with fat tissue, hemorrhage and fibrosis, positive for CD34 and CD31, thus compatible with the diagnosis of a cavernous hemangioma.

Discussion

Breast hemangiomas are found in 1.2% of mastectomy specimens and 11% of postmortem specimens of the female breast [6]. Recordings of breast hemangioma in the male breast are limited to very few reports, thus an exact incidence can't be determined.

Hemangiomas are part of the vascular tumors [4] and may be further subclassified into capillary, cavernous, venous, and perilobular [3-5]. The capillary type is formed by capillary size vessels. Cavernous are made of large dilated vessels, and are subdivided in several subtypes: parenchymal, nonparenchymal, or subcutaneous [7]. Parenchymal hemangiomas are mi-

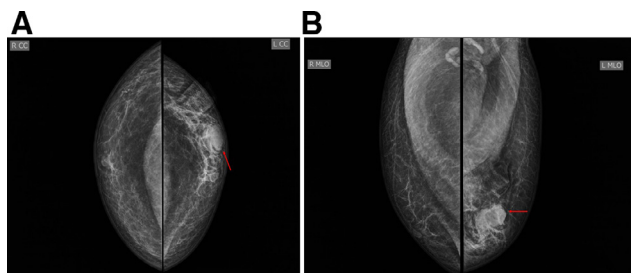


Fig. 2 – Craniocaudal (A) and Mediolateral Oblique views (B) showing a well circumscribed dense mass (red arrow) located at the left lower outer quadrant, without spiculation, calcification, or skin retraction. (Color version of figure is available online.)

croscopic lesions formed by dilated channels containing red blood cells [7]. Subcutaneous hemangiomas are located in the fat anterior to the pectoral fascia [7]. Venous hemangiomas are formed by large venous channels with disorganized vascular proliferation containing venous channels of 1-5 cm of diameter [3,7]. Perilobular hemangiomas have nuclear pleomorphism with no endothelial tufting and a perilobular location [3].

Clinical Features

Clinical diagnosis is difficult, the most common symptom is the presence of a palpable mass on the breast [4]. Even if the lesion is associated with change of the color of skin, the most common diagnosis in this setting is angiosarcoma [8].

Imaging features

Hemangiomas may be seen in mammographic series, appearing as a round or oval masses with sharp margins that may or may not contain calcifications [1,2]. When present, calcifications can be fine or coarse [7]. Ultrasound shows a solid lobulated well-defined mass with variable echo patterns, this may be secondary to the presence of phleboliths, vascular channels, and fibrous septation [1,2,4]. With Doppler the lesion may show vascular poles [1]. Magnetic resonance imaging shows a mass with intermediate signal intensity in T1 and hyperintense signal in T2 with cystic spaces [2]. If the lesion contains phleboliths, it may demonstrate low signal intensity foci [2]. With the administration of intravascular gadolinium the lesion shows typically early gradual centripetal enhancement which helps to differentiate from malignant tumors [2,8].

Because imaging features are nonspecific, differential diagnosis is broad [1] and must include benign and malignant lesions such as fibroadenoma, hematoma, arteriovenous malformations, fibrosarcoma, and angiosarcoma, among others [1].

The final diagnosis is always given by the histopathologic analysis [1]. Hemangiomas are typically positive for vascular markers such as CD31 and CD34 and negative for S-phase kinase and usually present with a Ki-67 index of 150-175 [2]. Given that CD34 and CD31 are also positive in angiosarcomas the differentiation between both should be based on the S-phase kinase (positive in angiosarcoma), a higher Ki-67 index, and the presence of atypia [2,5]

There has been debate in the topic of malignant transformation of hemangiomas to angiosarcomas, with some authors even doubting the existence of it [9]. Thus, we consider, that a breast lesion with imaging findings consistent with a benign vascular lesion and histological diagnosis of hemangioma in a core biopsy, may be followed up by imaging, without need of surgical excision.

Conclusion

The hemangioma is an extremely rare benign tumor of the breast in males with very few cases reported in the literature. Because imaging features are nonspecific the differential diagnosis is broad and may include benign and malignant lesions, usually requiring tissue sampling for a definite diagnosis. Although uncommon the breast imager must keep this vascular tumor as a possible diagnosis and know its imaging features.

REFERENCES

- [1] Farid F, Bulut T, Oosterhof-berktas R. Hemangioma in the male breast. *J Med Cases* 2016;7(8):323–5.
- [2] Lattin GE, Jesinger RA, Mattu R, Glassman LM. From the radiologic pathology archives: diseases of the male breast: radiologic-pathologic correlation. *Radiographics* 2013;33(2):461–89.
- [3] Roychowdhury M Hemangioma and angiomatosis of breast [Internet]. PathologyOutlines.com website. [cited <http://www.pathologyoutlines.com/topic/breasthemangioma.html>].
- [4] Aydın OU, Soylu L, Ercan Aİ, Bilezikçi B, Özbaş S. Cavernous hemangioma in the breast. *J Breast Heal* 2015;11(4):199–201.
- [5] Mango VL, Goodman S, Clarkin K, Wynn RT, Friedlander L, Hibshoosh H, et al. The unusual suspects: a review of unusual benign and malignant male breast imaging cases. *Clin Imaging* 2018;50(December 2017):78–85 Elsevier.
- [6] Lesueur GC, Brown RWBP. Incidence of perilobular hemangioma in the female breast. *Arch Pathol Lab Med* 1983;107(6):308–10.
- [7] Chidambaram A, Shetty M, Atula A. Cavernous haemangioma of male breast. *Int J Res Med Sci* 2013;1(4):571.
- [8] Vourtsi A, Zervoudis S, Pafiti A, Athanasiadis S. Male breast hemangioma—a rare entity: a case report and review of the literature. *Breast J* 2006;12(3):260–2.
- [9] Sygal V, Lalonde L, Dufresne M, Gagnon JH, Kao E. Sonographic and mammographic appearances of breast hemangioma. *Am J Roentgenol* 2008;191(July):17–22.